



Main Report

MedLEaPR - UTTAR PRADESH
POSTMORTEM HOUSE KGMU LUCKNOW
KGMU CHOWK LUCKNOW
FORM-VI

MEDICAL LEGAL REPORT- POST MORTEM EXAMINATION REPORT

PMR No(Generated by Software):- M431044902602298

Date:- 13/05/2026

PMR No(Given by Doctor):- 2264 / 2026

Date:- 13/05/2026

Sr No.	Doctor's Name	Designation	Registration No of Doctor with State Council/MCI	MLR/PMR Prepared by
1	DR MOUSAMI SINGH	Professor	49128	Yes
2	Dr Fathima Harsha P M	Senior Resident	70799	No
3	Dr Himanshu Patel	Junior Resident	97670	No

Victim Details:

Name Mr. PRATEEK YADAV
Relative Name(Father) LATE MULAYAM SINGH YADAV
Age(Approx) 39 Years 0 Months 0 Days
Gender MALE
Caste/Religion HINDU
Marital Status MARRIED
Occupation Business
Present Address 8 / 2 VIKRAMADITYA MARG, GAUTAMPALLI, LUCKNOW
Nationality Indian
State UTTAR PRADESH
District Lucknow Central (Commissionerate Lucknow)
Police Station GAUTAMPALLI
Date & Time of receipt of Inquest papers (in hrs) 13/05/2026 08:30 AM
Date & Time of receipt of body in the mortuary (in hrs) 13/05/2026 07:45 AM
Date and Time of Commencement of Autopsy (in hrs) 13/05/2026 09:30 AM
Whence brought/referral BROUGHT DEAD AT DR. S.P.M. CIVIL HOSPITAL, LUCKNOW ON DATED 13.05.2026 AT 05:55 AM, VIDE ENCLOSURE NO. 04.
Complete Date and Time of Autopsy (in hrs) 13/05/2026 10:30 AM

Police Accompanied : Yes

SrNo.	Name	Rank	Belt No	Police Station, District, State	Email	Phone	Signature
1	CP ROBIN SINGH	CONSTABLE	CP 2940	HAZRATGANJ, Lucknow Central (Commissionerate Lucknow), UTTAR PRADESH		8923644029	

Person Accompanied Detail: Yes

Sr No.	Name	Address	Relation with Patient	Police Station, District, State, Nationality	Signature
1	CHANDRA SHEIKHAR SINGH BISHT	31 GULISTA COLONY, GAUTAMPALLI, LUCKNOW	Wife's brother	GAUTAMPALLI, Lucknow Central (Commissionerate Lucknow), UTTAR PRADESH, Indian	

RSA Case: No

Marks of Identification

Sr No.	Identification Details
1	IDENTIFIED BODY
2	A TATTOO MARK (IMAGE OF SHIVLING) OF SIZE 17 CM X 10 CM, PRESENT OVER ANTERIOR ASPECT OF NECK. A TATTOO MARK (IMAGE OF FEMALE FACE) OF SIZE 22 CM X 25 CM, PRESENT OVER BACK OF CHEST, JUST BELOW THE LEFT SHOULDER. A TATTOO MARK (IMAGE OF FLOWER, DOG, WRITINGS OF BETI LIFE AND BEYOND ALWAYS WITH ME OCT 1. 2007) OF SIZE 27 CM X 14 CM, PRESENT ON VENTRAL ASPECT OF LEFT FOREARM. A TATTOO MARK (WRITINGS OF LAKSHYA IN HINDI) PRESENT OVER DORSAL LATERAL ASPECT OF LEFT HAND.
3	A TATTOO MARK (IMAGE OF FLOWER, DOG & WRITINGS OF DULAVIS FIRST BORN LALLA) SIZE OF 33 CM X 22 CM, PRESENT OVER LATERAL ASPECT OF RIGHT ARM INCLUDING SHOULDER. A TATTOO MARK (IMAGE OF SNAKE) OF SIZE 18 CM X 09 CM, PRESENT OVER DORSUM OF RIGHT FOREARM, WRIST & HAND.

In case of Hospital death : No

Information Supplied by the Police and/or Hospital Record (Symptoms Observed)
As Per Information Provided by Police
UNKNOWN CAUSE & BROUGHT DEAD AT DR. S.P.M. CIVIL HOSPITAL, LUCKNOW ON DATED 13.05.2026 AT 05:55 AM, VIDE ENCLOSURE NO. 02 & 04.
As Per Hospital Record
BROUGHT DEAD AT DR. S.P.M. CIVIL HOSPITAL, LUCKNOW ON DATED 13.05.2026 AT 05:55 AM, VIDE ENCLOSURE NO. 04.

General Description / Examination

Description of clothes/jewellery and other items worn on the body (Important areas be encircled on the clothing wherever possible and handed over to the police)	GREEN COLOUR T-SHIRT & BLACK COLOUR LOWER.
Length	176 cm
Weight(in Kgs)	96 kgs
Physique	Well Built
Rigor Mortis	Yes
Rigor Mortis Remarks	PRESENT ON ALL OVER THE BODY

Post mortem staining	PRESENT ON BACK OF THE BODY
Any Other Finding	OEDEMA PRESENT OVER BOTH LOWER LIMBS. DEAD BODY BROUGHT IN SEALED COVER.

External General Appearance	
State of eyes :	
Pupil(Rt)	DILATED / FIXED
Pupil(Lt)	DILATED / FIXED
Cornea/Conjunctiva(Rt)	HAZY
Cornea/Conjunctiva(Lt)	HAZY
Natural orifices(Please note presence of blood, froth etc in mouth, nose, ears (specify(Rt,Lt),anus,vagina and urethra)	BOTH HAND NAILS, BOTH EARS & LIPS ARE CYANOSED. EYES AND MOUTH CLOSED, REST N.A.D.
Any Other	1. OLD & HEALED LINEAR SCAR MARK OF SIZE 47 CM X 0.3 CM, PRESENT LONGITUDINALLY OVER ABDOMEN, 08 CM BELOW FROM THE UMBILICUS. 2. OLD & HEALED LINEAR SCAR MARK OF SIZE 31 CM X 0.4 CM, PRESENT OVER BOTH RIGHT AND LEFT GROIN FOLDS. 3. OLD & HEALED LINEAR SCAR MARK OF SIZE 1.5 CM X 0.4 CM, PRESENT OVER POSTERIOMEDIAL ASPECT OF LEFT KNEE JOINT. 4. OLD & HEALED LINEAR SCAR MARK OF SIZE 1.5 CM X 0.4 CM, PRESENT OVER POSTERIOMEDIAL ASPECT OF RIGHT KNEE JOINT. 5. OLD & HEALED LINEAR SCAR MARK OF SIZE 1.5 CM X 0.8 CM, PRESENT OVER LEFT THIGH ANTERIORLY JUST ABOVE THE KNEE JOINT. 6. MULTIPLE SCRATCH MARKS PRESENT ON ANTERIOR ASPECT OF RIGHT LEG WITH SCAB PRESENT. 7. MULTIPLE SCRATCH MARKS PRESENT OVER LEFT LEG, ANTERIORLY OVER AN AREA OF 10 CM X 06 CM, 19 CM BELOW FROM THE LEFT KNEE JOINT.

Injury Details: Yes

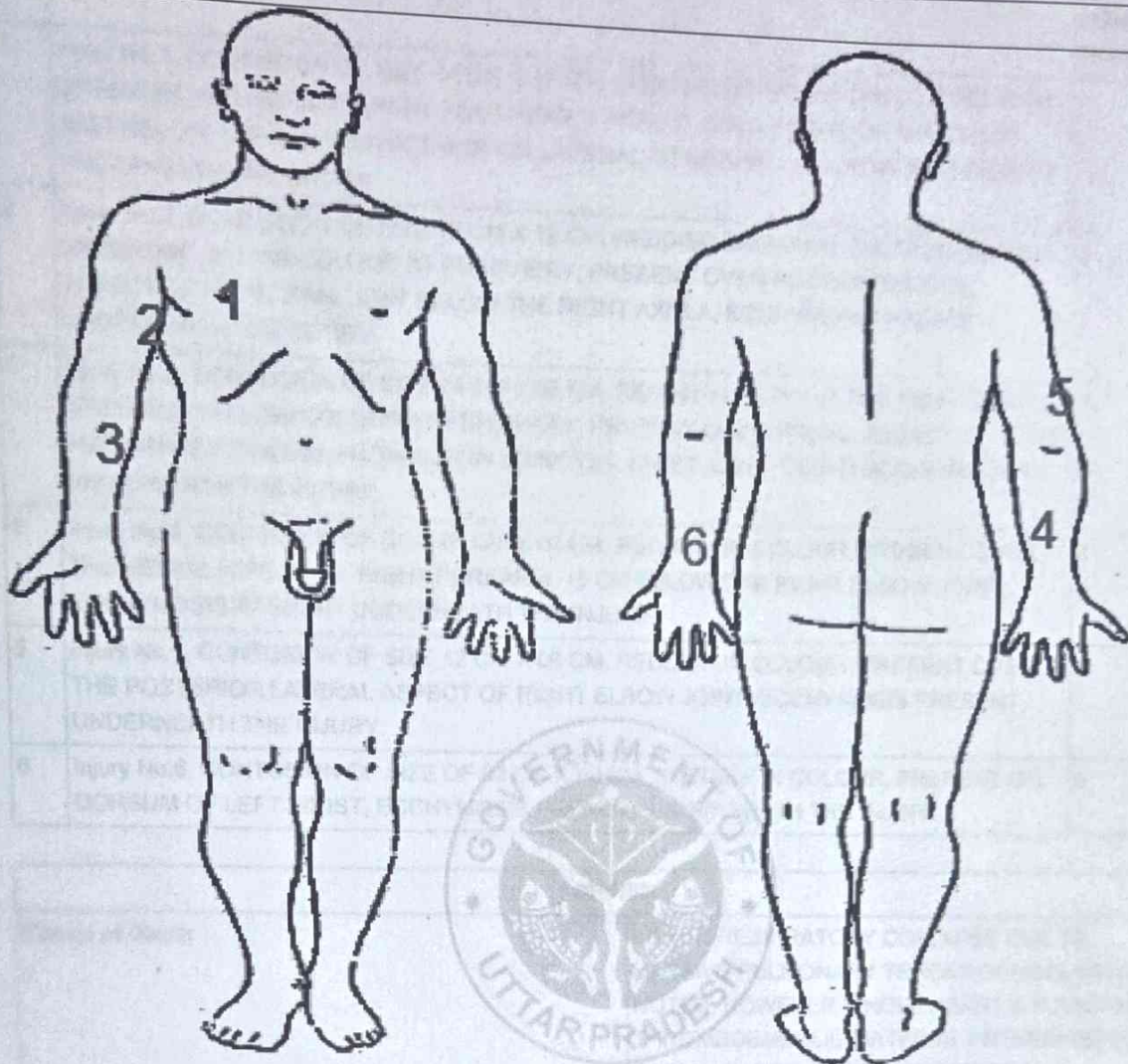
sno	Injury Details	Injury Number	Pictorial depiction?
1	CONTUSION OF SIZE 14 CM X 07 CM, REDDISH BROWN IN THE CENTRE WITH GREENISH YELLOW COLOUR AT PERIPHERY, PRESENT OVER FRONT OF THE CHEST, JUST BELOW THE RIGHT NIPPLE & 06 CM LATERAL TO MIDLINE, ECCHYMOSES PRESENT UNDERNEATH THE INJURY.	1	Yes
2	CONTUSION OF SIZE 19 CM X 12 CM, REDDISH BROWN IN THE CENTRE WITH GREENISH YELLOW COLOUR AT PERIPHERY, PRESENT OVER POSTERIOMEDIAL ASPECT OF RIGHT ARM, JUST BELOW THE RIGHT AXILLA, ECCHYMOSES PRESENT UNDERNEATH THE INJURY.	2	Yes
3	CONTUSION OF SIZE 24 CM X 08 CM, REDDISH BROWN IN THE CENTRE WITH GREENISH YELLOW COLOUR AT PERIPHERY, PRESENT OVER MEDIAL ASPECT OF RIGHT FOREARM EXTENDING FROM ELBOW JOINT TILL WRIST JOINT, ECCHYMOSES PRESENT UNDERNEATH THE INJURY.	3	Yes
4	CONTUSION OF SIZE 06 CM X 04 CM, REDDISH IN COLOUR, PRESENT OVER THE MEDIAL ASPECT OF RIGHT FOREARM, 15 CM BELOW THE RIGHT ELBOW JOINT, ECCHYMOSES PRESENT UNDERNEATH THE INJURY.	4	Yes
5	CONTUSION OF SIZE 12 CM X 06 CM, REDDISH IN COLOUR, PRESENT OVER THE POSTERIOR LATERAL ASPECT OF RIGHT ELBOW JOINT, ECCHYMOSES PRESENT UNDERNEATH THE INJURY.	5	Yes
6	CONTUSION OF SIZE OF 03 CM X 02 CM, REDDISH IN COLOUR, PRESENT ON DORSUM OF LEFT WRIST, ECCHYMOSES PRESENT UNDERNEATH THE INJURY.	6	Yes

S.No	Component	Remarks
1	Cranium & spinal Cord (Brain must be exposed in every case, Spinal cord need not to be examined except in case of injury to vertebral column/Spinal Cord)	
	Scalp	CONTUSION OF SIZE 06 CM X 05 CM PRESENT OVER LEFT TEMPORAL REGION, 07 CM BEHIND & POSTERIOR TO LEFT EAR. REDDISH CONTUSION OF SIZE 03 CM X 02 CM, PRESENT OVER RIGHT SIDE, 07 CM ABOVE FROM THE RIGHT EAR. ECCHYMOSES PRESENT UNDERNEATH THE ABOVE INJURY.
	Skull	NAD
	Meninges and Vessels	CONGESTED
	Brain	VESSELS CONGESTED, SUB ARACHNOID HAEMORRHAGE PRESENT OVER BOTH RIGHT & LEFT TEMPERO-PARIETAL REGION.
	Brain Weight (in grams)	1268 grams
	Vertebrae & Spinal Cord	NOT EXPOSED
2	Mouth, Pharynx & Oesophagus.	NAD
3	Neck	NAD
	Condition of neck tissues Thyroid	NAD
	Hyoid bone	NAD
	Larynx & Trachea	NAD

4	Thorax	
	Chest wall,Ribs/Sternum and Cartilage	ECCHYMOSIS OF SIZE 09 CM X 06 CM PRESENT OVER RIGHT CHEST WALL ANTERIOLATERAL ASPECT, JUST ABOVE LOWER RIB, REST NAD
	Pleura / pleural Cavity.	CONGESTED REST NAD
	Lung(Rt)	PARENCHYMA CONGESTED, PULMONARY ARTERY AND ITS MAIN BRANCHES STUDDERED, WITH FIRM, ADHERENT, THROMBO EMBOLIC MATERIAL OF REDDISH BROWN COLOUR, BRONCHUS AND ITS BRANCHES STUDDERED WITH MUCUS SECRETIONS.
	Lung(Rt) Weight (in grams)	410 grams
	Lung(Lt)	PARENCHYMA CONGESTED, PULMONARY ARTERY AND ITS MAIN BRANCHES STUDDERED, WITH FIRM, ADHERENT, THROMBO EMBOLIC MATERIAL OF REDDISH BROWN COLOUR, BRONCHUS AND ITS BRANCHES STUDDERED WITH MUCUS SECRETIONS.
	Lung(Lt) Weight (in grams)	424
	Pericardium	CONGESTED
	Heart	LEFT CHAMBERS ARE EMPTY & RIGHT CHAMBERS FILLED WITH CLOTTED BLOOD
	Heart Weight (in grams)	400 grams
	Coronary Arteries & Large Blood Vessel	NAD
5	Abdomen	
	Peritoneum, Retroperitoneum	CONGESTED
	Stomach and its contents	MUCOSA CONGESTED, ABOUT 50 ML OF CLEAR FLUID PRESENT
	Small Intestine and its content	DIGESTED FOOD AND GASES
	Large Intestine and its content	FECAL MATTER AND GASES PRESENT
	Liver and Gall Bladder	CONGESTED, GB HALF FILLED
	Liver and Gall Bladder Weight (in grams)	2036
	Spleen	CONGESTED
	Spleen Weight (in grams)	130 grams
	Pancreas	NAD
	Kidney(Rt.)	CONGESTED
	Kidney(Rt.) Weight (in grams)	198
	Kidney(Lt.)	CONGESTED
	Kidney(Lt.) Weight (in grams)	178
	Urinary Bladder	NAD

Muscles, bones and joints (Injury/Injuries,Diseases Deformity,Fractures,Dislocation)

AS NOTED



sno	Injury Details	Injury Number
1	Injury No.1, CONTUSION OF SIZE 14 CM X 07 CM, REDDISH BROWN IN THE CENTRE WITH GREENISH YELLOW COLOUR AT PERIPHERY, PRESENT OVER FRONT OF THE CHEST, JUST BELOW THE RIGHT NIPPLE & 06 CM LATERAL TO MIDLINE, ECCHYMOSIS PRESENT UNDERNEATH THE INJURY.	1
2	Injury No.2, CONTUSION OF SIZE 19 CM X 12 CM, REDDISH BROWN IN THE CENTRE WITH GREENISH YELLOW COLOUR AT PERIPHERY, PRESENT OVER POSTERIO-MEDIAL ASPECT OF RIGHT ARM, JUST BELOW THE RIGHT AXILLA, ECCHYMOSIS PRESENT UNDERNEATH THE INJURY.	2
3	Injury No.3, CONTUSION OF SIZE 24 CM X 08 CM, REDDISH BROWN IN THE CENTRE WITH GREENISH YELLOW COLOUR AT PERIPHERY, PRESENT OVER MEDIAL ASPECT OF RIGHT FOREARM EXTENDING FROM ELBOW JOINT TILL WRIST JOINT, ECCHYMOSIS PRESENT UNDERNEATH THE INJURY.	3
4	Injury No.4, CONTUSION OF SIZE 06 CM X 04 CM, REDDISH IN COLOUR, PRESENT OVER THE MEDIAL ASPECT OF RIGHT FOREARM, 15 CM BELOW THE RIGHT ELBOW JOINT, ECCHYMOSIS PRESENT UNDERNEATH THE INJURY.	4
5	Injury No.5, CONTUSION OF SIZE 12 CM X 06 CM, REDDISH IN COLOUR, PRESENT OVER THE POSTERIOR LATERAL ASPECT OF RIGHT ELBOW JOINT, ECCHYMOSIS PRESENT UNDERNEATH THE INJURY.	5
6	Injury No.6, CONTUSION OF SIZE OF 03 CM X 02 CM, REDDISH IN COLOUR, PRESENT ON DORSUM OF LEFT WRIST, ECCHYMOSIS PRESENT UNDERNEATH THE INJURY.	6

OPINION	
Cause of Death	CARDIORESPIRATORY COLLAPSE DUE TO MASSIVE PULMONARY THROMBOEMBOLISM AS NOTED, HOWEVER WHOLE HEART & PULMONARY THROMBOEMBOLIC MATERIAL PRESERVED IN FORMALIN FOR HISTOPATHOLOGICAL EXAMINATION AND VISCERA PRESERVED FOR CHEMICAL ANALYSIS AND HANDED OVER TO C.P. CONCERNED, VIDE VISCERA NO. 752 / 2026.
Antemortem/Postmortem	ALL INJURIES MENTIONED ARE ANTEMORTEM
Probable time	
a. Between injury and death	INJURIES 1,2,3 ARE ABOUT 05 TO 07 DAYS OLD. INJURIES 4,5,6 ARE ABOUT ONE DAY OLD.
b. Between death and postmortem examination	ABOUT HALF DAY

Details of Doctor/s who examined the patient with signature:					
SrNo.	Doctor's Name	Designation	Registration Details	MLR/PMR Prepared by	Signature
1	DR MOUSAMI SINGH	Professor	49128	Yes	
2	Dr Fathima Harsha P M	Senior Resident	70799	No	
3	Dr Himanshu Patel	Junior Resident	97670	No	

Transaction Id :- M431044902602298

Page 7 of 8

Report Generated Date: 13/05/2026 13:29:13.55

डिप्टी कमिश्नर अचिकासी
श्री विवेक
पोस्टमॉर्टम हाउस के जी.एन.यू. लखनऊ

POSTMORTEM HOUSE KGMU LUCKNOW KGMU CHOWK LUCKNOW, UTTAR PRADESH

Handed over to the Police

Dead body after post-mortem examination duly stitched.

Belongings of the deceased : Sealed

SAMPLE OF SEAL, SEALED JAR CONTAINING WHOLE HEART AND SEALED VIAL CONTAINING THROMBOEMBOLIC MATERIAL FOR HISTOPATHOLOGY & SEVEN SEALED VIALS OF VISCERA FOR CHEMICAL ANALYSIS.

Post Mortem Examination Report

Police Inquest Paper(s) Numbering 1 to 09

Any Other Detail :

ALL THE DOCTORS ARE POSTED IN DEPARTMENT OF FORENSIC MEDICINE AND TOXICOLOGY , KGMU LUCKNOW. VIDEOGRAPHY TAKEN BY Mr.SAURAB YADAV, POLICE CONTROL ROOM , KAISERBAGH,LUCKNOW.

Robin Singh
Received

(Signature of Officer)

Officer Name :ROBIN SINGH

Date:13/05/2026

Belt Number:2940

Police Station:HAZRATGANJ, LKO

Viscera Details:

- 1-Pc. of Stomach
- 2-Pc. of Small Intestine
- 3-Pc. of Liver
- 4-Pc. of Kidney
- 5-Pc. of Spleen
- 6-Pc. of Stomach Contents
- 7-Blood Sample



Signature valid

Digitally signed by DR MOUSAMI SINGH

Date: 2026.05.13 13:30:54 IST